Neurosurgical Review (2024) 47:40
https://doi.org/10.1007/s10143-023-02270-3

RESEARCH

Continuous irrigation with thrombolytics for intraventricular hemorrhage: case–control study

Diego A. Carrera[1] · Marc C. Mabray[2] · Michel T. Torbey[1] · Jason E. Andrada[1] · Danika E. Nelson[3] · Preeyaporn Sarangarm[4] · Heather Spader[5] · Chad D. Cole[5] · Andrew P. Carlson[1,5]

Received: 23 October 2023 / Revised: 25 December 2023 / Accepted: 29 December 2023

Abstract

Intraventricular hemorrhage (IVH) is a complication of a spontaneous intracerebral hemorrhage. Standard treatment is with external ventricular drain (EVD). Intraventricular thrombolysis may improve mortality but does not improve functional outcomes. We present our initial experience with a novel irrigating EVD (IRRAflow) that automates continuous irrigation with thrombolysis.

Single-center case–control study including patients with IVH treated with EVD compared to IRRAflow. We compared standard demographics, treatment, and outcome parameters between groups. We developed a brain phantom injected with a human clot and assessed clot clearance using EVD/IRRAflow approaches with CT imaging.

Twenty-one patients were treated with standard EVD and 9 patients with IRRAflow. Demographics were similar between groups. Thirty-three percent of patients with EVD also had at least one dose of t-PA and 89% of patients with IRRAflow received irrigation with t-PA ($p = 0.01$). Mean drain days were 8.8 for EVD versus 4.1 for IRRAflow ($p = 0.02$). Days-to-clearance of ventricular outflow was 5.8 for EVD versus 2.5 for IRRAflow ($p = 0.02$). Overall clearance was not different. Thirty-seven percent of EVD patients achieved good outcome (mRS ≥ 3) at 90 days versus 86% of IRRAflow patients ($p = 0.03$). Assessing only t-PA, reduction in mean days-to-clearance ($p = 0.0004$) and ICU days ($p = 0.04$) was observed. In the benchtop model, the clot treated with IRRAflow and t-PA showed a significant reduction of volume compared to control. Irrigation with IRRAflow and t-PA is feasible and safe for patients with IVH. Improving clot clearance with IRRAflow may result in improved clinical outcomes and should be incorporated into randomized trials.

Keywords Continuous irrigation · Intraventricular hemorrhage · Intraventricular thrombolysis · Intracerebral hemorrhage

Introduction

Intraventricular hemorrhage (IVH) as an extension of a spontaneous intracerebral hemorrhage (sICH) is a frequent complication [1] that aggravates the outcomes of this type of stroke [1–7]. One of the major complications of IVH is the mechanical obstruction of the 3rd and 4th ventricles leading to obstructive hydrocephalus as well as secondary brain injury from blood breakdown products [8, 9]. The mainstay of treatment for obstructive hydrocephalus involves the placement of an external ventricular drain (EVD) for intracranial pressure (ICP) monitoring and cerebrospinal fluid (CSF) diversion as necessary, in preference to medical management alone [10]. Such an approach is frequently complicated by drain clotting with some series reporting as high as 60% obstruction rates [11], need for drain replacement [12], or bilateral EVD placement for casted ventricles

Previous presentations: none.

✉ Andrew P. Carlson
AndrewCarlson@salud.unm.edu

1 Department of Neurology, University of New Mexico, Albuquerque, NM, USA

2 Department of Radiology, University of New Mexico, Albuquerque, NM, USA

3 School of Medicine, University of New Mexico, Albuquerque, NM, USA

4 Department of Pharmacy, University of New Mexico Hospital, Albuquerque, NM, USA

5 Department of Neurosurgery, University of New Mexico School of Medicine, Albuquerque, NM 87131, USA

Published online: 10 January 2024

[13]. Mortality is greater than 50% with only 20–40% of survivors having good functional outcomes [13–15]. The need for long-term interventions such as ventriculoperitoneal shunting (VPS) is around 20% [13].

Intraventricular thrombolysis through the EVD using intermittent boluses of recombinant tissue plasminogen activator (t-PA) has been tested compared to saline control injections and has been shown to be safe with a mortality benefit [10]. Despite this benefit, a definite impact on functional outcome has not been established [13]. Nonetheless, these data suggest that there may be an association between enhanced IVH clearance and better functional outcomes [13, 16, 17]. From a practical perspective, intraventricular thrombolysis is widely used to maintain catheter patency [18].

Recent approaches to improve care for patients with IVH have focused on the potential benefit of enhancing clot volume reduction, which has been associated with better outcomes [13, 16, 17]. In addition, better delivery methods that limit the need for continuous breaking of the sterile circuit may improve the safety and efficacy of intraventricular thrombolysis [19, 20]. The recent development of an automatic irrigating catheter (IRRAflow) that uses continuous ICP measurements as a feedback mechanism offers the potential to deliver continuous boluses of irrigation alone or irrigation with t-PA [19]. This cycling feedback process of ICP measurement, irrigation, and drainage is intended to prevent overirrigation using a bedside control unit and has been shown to be safe in IVH associated to sICH [19] and subarachnoid hemorrhage [20].

We present a case–control study comparing patients who underwent placement of a standard EVD with and without intraventricular t-PA to those who underwent placement of the IRRAflow catheter with continuous irrigation with and without t-PA, assessing relevant safety and efficacy outcomes. In addition, we show a benchtop human clot model embedded in a brain phantom made of Agar comparing clot clearance rates using EVD with intermittent boluses of t-PA versus constant irrigation with t-PA using the IRRAflow device. We hypothesize that the use of IRRAflow with continuous irrigation with t-PA is feasible and safe providing a predictable method of severe IVH removal with a high burden of clot reduction when compared to the standard of care, which can be used in larger studies to assess functional outcomes.

Methods

Study design, procedure, and participants

We conducted a single-center case–control study with patients who were diagnosed with spontaneous intracerebral or cerebellar hemorrhage and intraventricular extension causing hydrocephalus requiring CSF diversion who were treated with the IRRAflow device or standard EVD from January 2019 through September 2022. Patients who had a diagnosis of cerebral amyloid angiopathy and intracerebral tumor or trauma were excluded, as well as those who required surgical decompression. Lobar hemorrhages were excluded to focus only on deep sICH with IVH.

EVD or IRRAflow was placed per clinical standard of care based on the preference of the neurosurgery attending. Briefly, after a standard twist drill hole was created, the IRRAflow catheter was reverse-tunneled using a plastic sheath. In cases where stereotactic navigation was used, a Peel-Away Sheath Introducer was placed using navigation, and the IRRAflow catheter was placed through the peel-away sheath, identical to the standard MISTIE approach for ICH [21].

Patients who were treated with the IRRAflow device received intraventricular irrigation with alteplase (Activase, Genentech Inc – USA, NDC 50242–085-25) or saline alone. Briefly, the goal was to set the infusion rate on the IRRAflow device to deliver alteplase within the range of the reported doses in earlier CLEAR trials [15]. Patients treated with EVD received intermittent boluses of alteplase based on the clinical judgement of the treating physician, in doses of 3 mg every 12 h or 2 mg every 8 h, delivering a total of 6 mg per day. For the IRRAflow group, using a pharmacy-approved protocol, we admixed alteplase 4 mg in 500 mL of preservative-free normal saline and irrigated at a rate of 30 mL/h as we have previously described [19], requiring a total of 720 mL per day, equivalent to 5.76 mg of alteplase per day. In practice, given the cycling nature of the active fluid exchange mechanism of the IRRAflow device (measure ICPs, drain, irrigate), the volume delivered was less, affecting the dose of alteplase that was effectively administered. Informed consent was obtained prior to either procedure. IRRAflow is an FDA-approved device, therefore not considered an investigational device.

We retrospectively collected IRRAflow cases and patients who required CSF diversion with standard-of-care EVD during the same period under an IRB-approved protocol (UNM HRPO# 21–051). We recorded standard demographics and characteristics of clinical presentation. We documented outcome parameters of the interventions, including modified Graeb score (mGS) before and after removal of drain (calculated as described previously [22]), number of days with drain, successful clearance of 3rd and 4th ventricles (defined as computed tomography (CT) evidence of interval absence of hyperdensity in the 3rd and 4th ventricles), number of days from the placement of the drain to successful clearance of the 3rd and 4th ventricles, need for ventriculoperitoneal shunt (VPS) placement as a long-term treatment for CSF diversion, need for EVD replacement, diagnosis of ventriculitis requiring antibiotic treatment, presence of

Grade 3 catheter tract hemorrhage as described previously [23], days of stay in the intensive care unit, and modified Rankin Score (mRS) upon discharge and at 90 days after discharge. Continuous data were compared with unpaired *t*-tests and categorical data were compared using Fisher's exact test or chi-square test. Significance was set at $p = 0.05$. Logistic regression was performed for the primary outcomes of good outcome (mRS 0–3) and mortality at discharge and around 90 days. All calculations were done using PRISM 9.5.1 (GraphPad Software Inc—MA, USA). No correction for multiple comparisons was used given the exploratory nature of the analysis and < 20 variables assessed. All data are presented as mean or percentage, unless otherwise specified. This study was made following the recommendations of the STROBE statement [24].

Bench study

We developed a bench model to test a human clot under different thrombolytic conditions. First, we made a brain phantom using agar gel as previously described [25, 26]. Briefly, we mixed agar (Sigma – USA, Cat No. A7921) with 1 × TBE buffer (Promega—USA. Cat No. V4251) at a concentration of 0.6% w/v and allowed it to boil for 5 min while mixing. When the mixture reached 50 °C, we poured it into a 1 L polymethyl methacrylate container and let it cool on an ice block. Once the center of the phantom reached 25 °C, we infused 50–60 mL of the previously made clot mixture, using a 50 mL syringe attached to a 14G IV catheter. To generate the clot, we salvaged an expired unit of whole blood and one of plasma from the blood bank and centrifuged the whole blood at 1200 rpm at 20 °C for 20 min and then pipetted out the plasma to combine it with the platelets. We added thrombin (Pfizer – USA, NDC 60793–315-01) and mixed for 2 min and subsequently added CaCl 5% (Sigma – USA, Cat No. C1016) to the mixture of red blood cells (RBCs) and buffy coat, using a ratio of RBCs + buffy coat to plasma + platelets of 1:10, as described previously [27]. The embedded clots were allowed to rest for 6 h and were imaged using CT every 24 h for 3 days. CTs were performed with a standard protocol on the same Siemens Biograph 64 PET/CT (CT only used) using energy of 100 peak kilovoltage (kVp) and tube current of 275 milliampere-seconds (mAs). Standard head CT reformats were made including 1 mm thick reformats used for measurements. Each clot was assigned to an intervention group: control (no intervention), EVD + t-PA, IRRAflow + saline, and IRRAflow + t-PA. The EVD + t-PA group received intermittent boluses of t-PA every 8 h, per CLEAR protocol [13]. The IRRAflow + saline and IRRAflow + t-PA groups received constant irrigation at a rate of 30 mL/h with either saline alone or alteplase at the concentration described previously [20]. We calculated clot volumes using the ABC/2 formula through the local PACS platform (IntelliSpace Radiology Enterprise 4.5, Philips – Netherlands). Data were analyzed with Dunnett's multiple comparisons test with a type I error rate of 0.05, using PRISM 6.01.

Results

Thirty subjects were identified who met inclusion criteria: 21 were treated with standard EVD and 9 were treated with the IRRAflow device. Demographic information and baseline severity factors are summarized in Table 1 and were similar between groups ($p > 0.05$). The mean Glasgow Coma Scale (GCS) was 10 in the EVD group and 12 in the IRRAflow group ($p = 0.21$). Rates of ICH score of 3 or 4 were similar (38% in the EVD group and 33% in the IRRAflow group [$p > 0.99$]). Graeb scores were also similar ($p = 0.21$).

Variation in treatment approaches between groups was significant, with a lower threshold to use t-PA in the IRRAflow group (89% in the IRRAflow group versus 33% in the EVD group [$p = 0.01$]). In addition, nearly all patients with IRRAflow who had a supratentorial hemorrhage had the drain placed ipsilateral to the clot (83%) while nearly all the EVD patients with supratentorial hemorrhage had the EVD placed contralateral to the clot (84%).

Outcomes

The use of IRRAflow was associated with improvements in multiple outcome variables (Table 1). The number of drain days was significantly less (4.1 versus 8.8 [= 0.02]). Days-to-clearance of the ventricular outflow was also less (2.5 versus 5.8 [$p = 0.02$]). However, the rate of overall clearance of the 3rd and 4th ventricles was not statistically different. No EVD replacement or VPS was required in the IRRAflow group; however, two patients with EVD required replacement and two required VPS. Functional outcomes were non-significantly better in the IRRAflow group at discharge (OR = 2.13, 95% CI [0.34–12.71]), however improved and became significantly better at 90 days, likely due to ongoing clinical improvement in survivors (OR = 10.29, 95% CI [1.372–216.4]) (Fig. 1).

In a subgroup analysis, selecting only patients who received treatment with t-PA, the trends were similar (Fig. 2). The IRRAflow group showed fewer days-to-clearance of ventricular outflow (1.9 versus 7.4 [$p = 0.0004$]), less drain days (3.7 versus 10.6 [$p = 0.0098$], and less ICU days (9.9 versus 23.2 [$p = 0.04$]).

Figure 3 demonstrates an illustrative case of this approach. In this subject, there was a small right caudate hemorrhage with a casted right lateral ventricle. The IRRAflow catheter was placed using the procedure described in the "Methods" section. A peel-away sheath was placed

directly into the casted ventricle using stereotactic guidance. The IRRAflow catheter was placed down the peel-away sheath. As expected, there was no initial CSF and minimal bloody drainage. During the first 24 h after the placement of the IRRAflow catheter, irrigation with saline alone did not achieve any observable clearance of the IVH. After starting irrigation with t-PA, the ventricular outflow was restored within 24 h. These results are consistent with the observations from our benchtop model.

In vitro clot reduction

We performed clot simulation in 4 simultaneous conditions as described above. IRRAflow with t-PA was the most effective strategy for clot reduction, reducing to a final volume of 10.6 mL (12% of initial clot volume). EVD with intermittent t-PA bolusing performed similarly to IRRAflow with saline irrigation. The control sample without drainage remained relatively stable over the 72 h of treatment (Fig. 4). Qualitatively, there was an area of hypodense "halo" observed within the clot surrounding the tip of the catheter in the IRRAflow with the t-PA group that was not present in the other comparators (Fig. 5), accounting for the enhanced clot clearance in this group.

Discussion

IVH is a severe complication of ICH that is associated with worse outcomes [27]. This may present some of the strongest opportunities for neurosurgical therapies to improve outcomes. In most cases with hydrocephalus in patients who are deemed salvageable, an EVD is necessary [10]. CSF diversion is often limited due to immediate drain obstruction due to drain placement in a casted ventricle. Therefore, many advocate for placing the EVD in the contralateral ventricle, which was the standard practice in most of our EVD cases. The limitation of a contralateral drain placement is the possibility of worsening the midline shift and subfalcine herniation, and it may not effectively clear blood from the casted ventricle [28]. For that reason, some authors advocate for bilateral EVD placement in such cases [29].

We developed a different solution to this problem like the clot-targeted approach used in MISTIE [21]. Using stereotactic guidance, the catheter is placed directly into the thickest part of the IVH. By using continuous irrigation, we did not experience any cases of catheter obstruction in this group. t-PA was typically started only after stability CT showing the adequate position of the catheter in the clot. Using this approach, we achieved clearance of the ventricular outflow in less time than the standard

Table 1 Demographics and outcomes

	Standard EVD ($n=21$)	IRRAflow ($n=9$)	p value
Demographics:			
Age (mean)	59	55	0.44
Sex (%female)	33%	44%	0.43
Baseline Graeb score (mean)	13	16	0.24
Baseline ICH score (% 3–4)	38%	33%	> 0.99
Admission GCS (mean)	10	12	0.21
Treatment variables:			
t-PA used (%)	33%	89%	0.01
Graeb score after removal (mean)	2	3	0.61
Drain days (mean)	8.8	4.1	0.02
Successful clearance of 3rd and 4th ventricle (%)	52%	89%	0.10
Days-to-clearance (mean)	5.8	2.5	0.02
VPS (%)	15%	0%	0.5
Need for EVD replacement (%)	39%	0%	0.04
Antibiotic-treated ventriculitis (%)	15%	0%	0.5
Tract hemorrhage > 5 cc (%)	24%	22%	> 0.99
ICU days (mean)	13.4	10.1	0.23
Good outcome (mRS ≤ 3) at DC (%)	19%	33%	0.40
Good outcome (mRS ≤ 3) at 90 days (%)	37%	86%	0.03

ICH intracerebral hemorrhage

GCS Glasgow Coma Scale

EVD external ventricular drain

VPS ventriculoperitoneal shunt

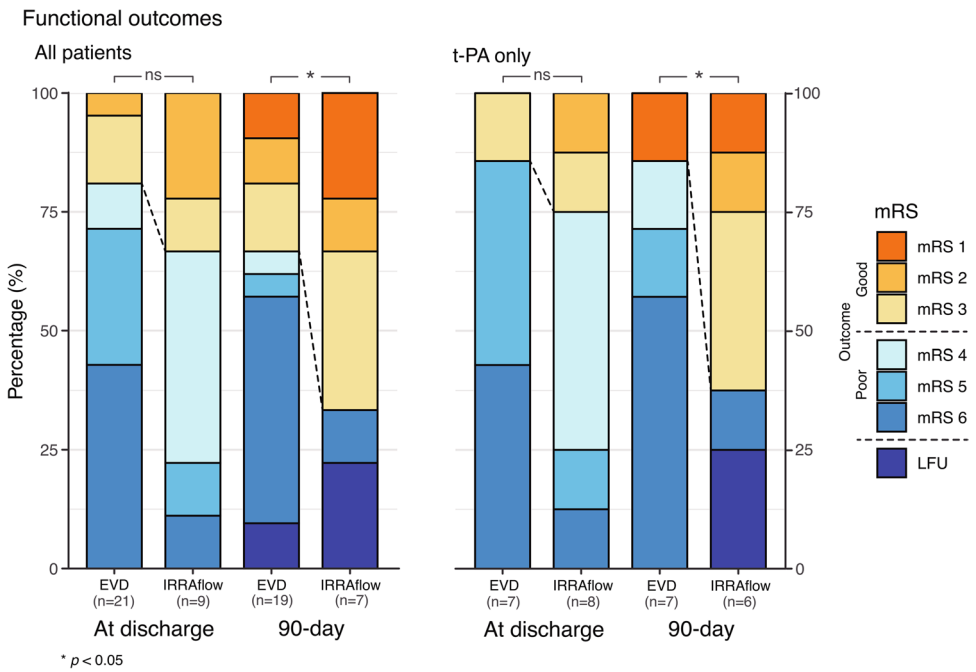

Fig. 1 Functional outcomes at discharge and 90 days after discharge by treatment group. Stacked bar plots illustrate percentages based on modified Rankin Score (mRS), ranging from mRS 0 (no disability, not shown) to mRS 6 (deceased); lost in follow-up (LFU) patients who did not return for follow-up were not included in the calculations for comparison, as shown by the total number of patients at the bottom of each bar (*n*). Good outcome was defined as mRS ≤ 3 and is highlighted with dotted lines to depict the difference between groups. For all the study population (left panel), the percentages included all patients who received intraventricular t-PA or drainage alone. The functional outcome was better in the IRRAflow group at 90 days after discharge ($p = 0.02$). For the t-PA-only subgroup (right panel), the analysis only included the patients who were treated with t-PA. The functional outcome was better in the IRRAflow group at 90 days after discharge ($p = 0.01$)

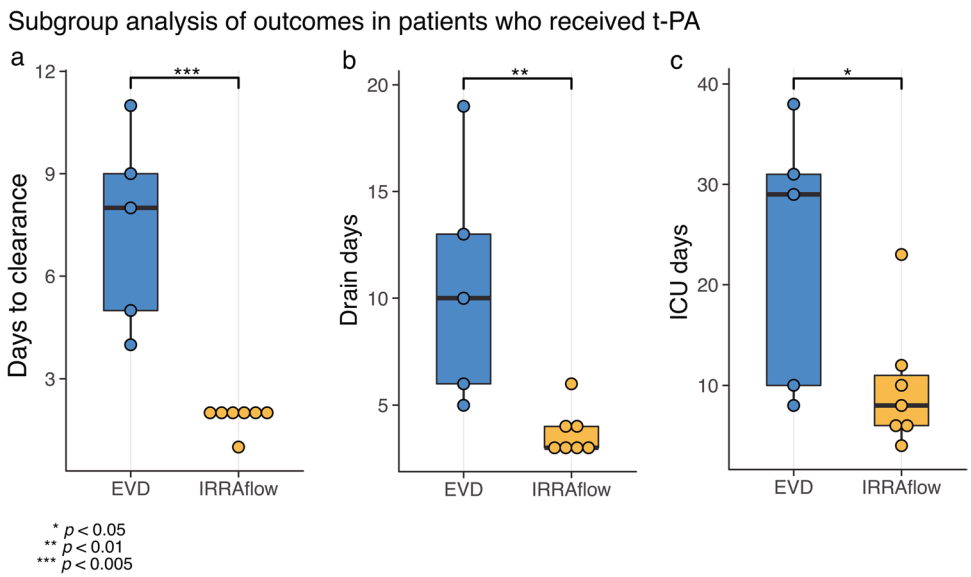

Fig. 2 Subgroup analysis comparing outcomes in patients who received intraventricular thrombolysis with t-PA. Barplots showing variables measured in patients who were treated with EVD (blue) or IRRAflow (orange). IRRAflow group showed better outcomes for the following variables: (**a**) days-to-clearance ($p = 0.0004$), (**b**) drain days ($p = 0.0098$), **c** ICU days ($p = 0.04$)

EVD group, suggesting that this technique may allow for faster treatment of hydrocephalus and significantly enhanced clot clearance as shown in our bench study. The subgroup analysis of outcomes shows improvement in functional outcomes at 90 days with IRRAflow (Fig. 1) suggesting a possible association between significantly shorter intervention times (Fig. 2) and better functional outcomes. The rationale for this association may be related to the known mechanisms by which prolonged exposure to breakdown blood products in an IVH leads to secondary

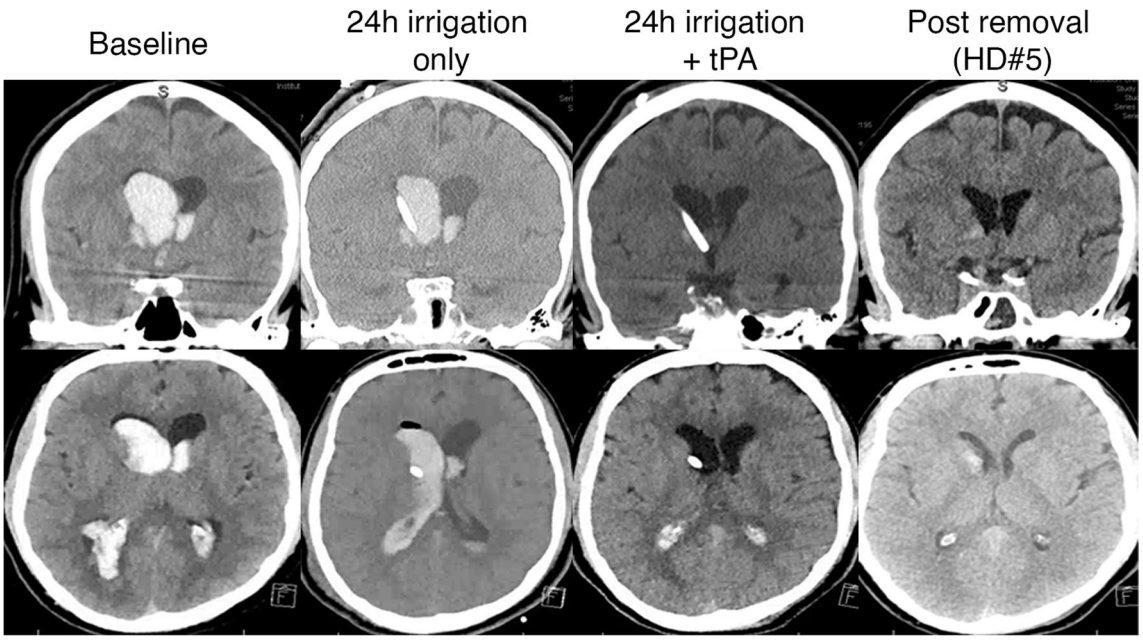

Fig. 3 CT images obtained at different time points before and after starting irrigation with t-PA in a patient treated with IRRAflow. Coronal (up) and axial (down) plane images are shown for each time point. "Baseline" images were obtained upon admission. "24-h irrigation only" was obtained after 24 h with irrigation with saline. "24h irrigation + t-PA" was obtained after 24 h of irrigation with t-PA, which continued until the 3rd ventricle was cleared, per our protocol. Drain was removed on hospital day (HD) #5 without any significant complications

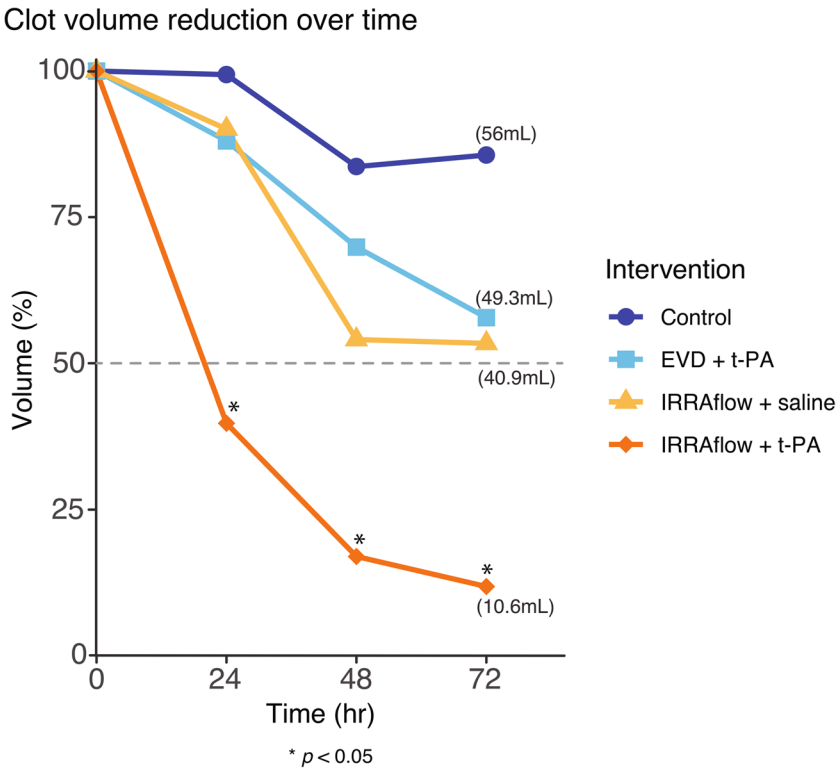

Fig. 4 Line plot depicting clot volume reduction over time in the pre-clinical clot model. Four groups are shown: Control (grey), EVD + t-PA (blue), IRRAflow + saline (orange), and IRRAflow + t-PA (red). Volume (*Y* axis) is expressed as percentage (%) vs time (*X* axis) expressed in hours (hr). Significance ($p < 0.05$) was calculated comparing the intervention groups (EVD + t-PA, IRRAflow + saline, IRRAflow + t-PA) with the control group using Dunnett's multiple comparison test. A significant reduction in clot volume was achieved in the IRRAflow + t-PA group, resulting in a greater than 50% clot reduction within the first 24 h of intervention

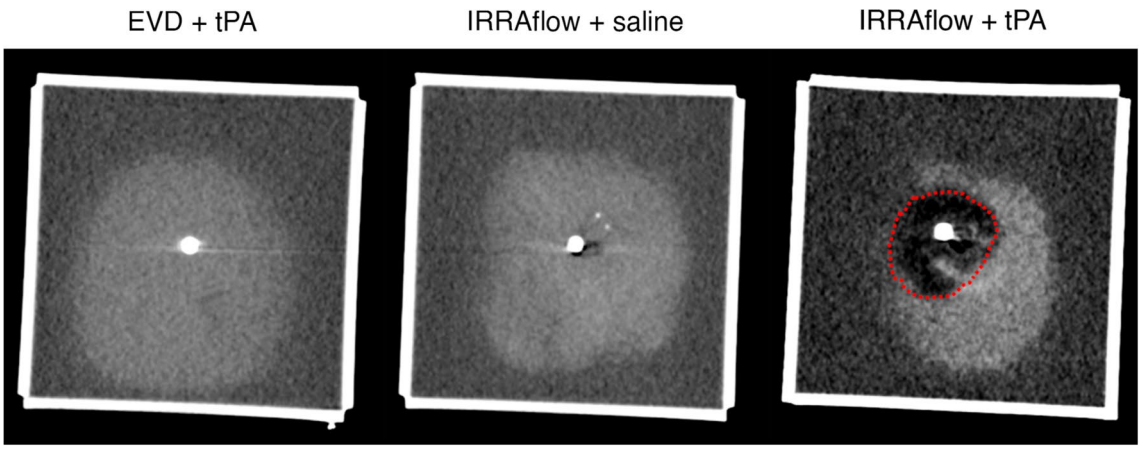

Fig. 5 CT images of brain phantoms with embedded human clots that underwent different thrombolytic interventions after 24 h of treatment. The picture on the left shows EVD + t-PA, the middle picture shows IRRAflow + saline, and the right picture shows IRRAflow + t-PA. In dotted red line, highlighting the "fibrinolytic halo" only present in the IRRAflow + t-PA group, showing enhanced clot clearance

brain injury, impairing CSF dynamics and even causing hydrocephalus [9]. Although the difference in overall clearance of ventricles was not significant between groups at the end of the treatment, reducing the time-to-clearance may be beneficial and relevant to reduce complications related to prolonged drain times [30, 31]. In CLEAR III, nearly one-third of patients required ICP-lowering therapies and similar numbers required bilateral EVD, suggesting the need for earlier ventricular decompression. Our approach efficiently overcomes most of the reported limitations of the contralateral EVD placement in IVH.

Despite only including the drain-associated complications in Table 1, we did not include other medical complications that arise in the intensive care unit (ICU) such as nosocomial infections and other complications inherent to our study population [32], which could account for a not statistically significant difference in overall ICU stay. Although we expect that by increasing the power of the sample, this difference may become significant.

Furthermore, the use of EVD is associated with multiple complications that can also contribute to worse outcomes. In our small series, none of the patients treated with the IRRAflow required EVD replacement or permanent VPS, consistent with the published literature [33]; whereas the complication rate in the control arm was closer to 18%, as reported in CLEAR III. Interestingly, the tract hemorrhage rate was similar. However, in the IRRAflow group, these were not clinically significant and resolved with irrigation, while many of these led to additional drain replacements in the EVD group. Multiple studies have demonstrated the relatively high incidence of complications with EVD placement [23, 34–36]. Therefore, improving the safety profile of the treatment itself by reducing complications that may require drain replacement is of preeminent need. Figure 4 summarizes the enhanced intraventricular clot clearance after irrigation with t-PA as early as 24 h after starting the intervention, which clinically translates to improvement of hydrocephalus.

Our clot model data is consistent with our experience. The use of t-PA appears to be the fastest for ventricular clearance; however, irrigation alone may have more efficacy than drainage alone. The rationale for this finding lies in enhancing clot clearance by combining chemical and mechanical clot erosion (irrigation with t-PA) versus only mechanical erosion (irrigation with saline), in comparison to drainage alone.

Currently, other treatment alternatives include neuroendoscopic approaches with varied outcomes that mainly rely on surgical expertise [37–44]. Endoscopic removal of IVH may result in a more invasive procedure compared to constant irrigation with t-PA using an IRRAflow device. Even accounting for the learning curve involved in the reverse-tunnelling technique required for the IRRAflow catheter placement, it may be more accessible to the average surgeon when compared to other approaches.

Limitations

There are notable limitations to this preliminary study. Our sample size is underpowered, and the treatment approaches differed between groups. Though patients were generally treated based on physician preference, there was a crossover between techniques or other unmeasured factors that could introduce bias. The use of t-PA was more frequent in the IRRAflow group, possibly due to an overall

more aggressive approach. Prospective, randomized data are needed to better define the benefit of continuous irrigation with t-PA compared to standard EVD drainage for IVH.

Conclusion

The use of IRRAflow is feasible and safe in the setting of IVH. Moreover, it appears to be associated with fewer complications than standard EVD. IVH clearance overall is not significantly different, but the time-to-clearance is, and there may be efficacy in terms of improved clinical outcomes, favoring continuous irrigation with t-PA over intermittent boluses. A bench model confirms superior clot clearance with t-PA continuous irrigation when compared to controls of irrigation with saline alone, intermittent t-PA bolus, and drainage only. These findings support future use in clinical trials to assess whether this treatment modality can be associated with better functional outcomes.

Acknowledgements We would like to acknowledge Mr. Mark Raines for his assistance with the development of the containers for the benchtop model, and Dr. Rebecca Lamoureux PhD and Michele Wanner RT for the assistance with CT scans on the benchtop models.

Author contributions D.C. collected data, designed and performed benchtop experiments, conducted statistical analysis, wrote the manuscript, prepared all figures. M.B. designed and interpreted benchtop experiments. M.T., H.S. and C.C. conceptualized study design. J.A. collected data and conducted statistical analysis. D.N. collected data and performed benchtop experiments. P.S. conceptualized drug protocols. A.C. designed and supervised study, collected data, conducted statistical analysis, wrote the manuscript, prepared all figures. All authors reviewed the manuscript.

Funding No direct funds or review of this work from IRRAS. Carlson: previous grant/professional services funding from IRRAS. NIH P20GM109089 for salary support. Laboratory facilities were funded by the UNM Clinical & Translational Science Center (CTSC), supported by an award from the National Center for Advancing Translational Sciences, NIH UL1TR001449. The authors have no relevant financial or non-financial interests to disclose.

Data Availability Not applicable.

Declarations

Ethics approval This study was performed in line with the principles of the Declaration of Helsinki. Approval was granted by the Office of the Institutional Review Board at the University of New Mexico via IRB-approved protocol UNM HRPO# 21–051.

Consent to participate and consent for publication Not applicable.

Competing interests No direct funds or review of this work from IRRAS. A. C.: previous grant/professional services funding from IRRAS. The rest of the authors have no relevant financial or non-financial interests to disclose.

References

1. Bhattathiri PS, Gregson B, Prasad KS, Mendelow AD (2006) Intraventricular hemorrhage and hydrocephalus after spontaneous intracerebral hemorrhage: results from the STICH trial. Acta Neurochir Suppl 96:65–68
2. Weinstein R, Ess K, Sirdar B, Song S, Cutting S (2017) Primary intraventricular hemorrhage: clinical characteristics and outcomes. J Stroke Cerebrovasc Dis 26(5):995–999
3. Nieuwkamp DJ, de Gans K, Rinkel GJE, Algra A (2000) Treatment and outcome of severe intraventricular extension in patients with subarachnoid or intracerebral hemorrhage: a systematic review of the literature. J Neurol 247(2):117–121
4. Roeder SS, Sprügel MI, Sembill JA, Giede-Jeppe A, Macha K, Madžar D et al (2019) Influence of the extent of intraventricular hemorrhage on functional outcome and mortality in intracerebral hemorrhage. Cerebrovasc Dis 47(5–6):245–252
5. Hwang BY, Bruce SS, Appelboom G, Piazza MA, Carpenter AM, Gigante PR et al (2012) Evaluation of intraventricular hemorrhage assessment methods for predicting outcome following intracerebral hemorrhage. J Neurosurg 116(1):185–192
6. Nam TM, Jang JH, Kim SH, Kim KH, Kim YZ (2021) Comparative analysis of the patients with spontaneous thalamic hemorrhage with concurrent intraventricular hemorrhage and those without intraventricular hemorrhage. J Korean Med Sci 36(1):e4
7. Roh DJ, Asonye IS, Carvalho Poyraz F, Magid-Bernstein JR, Joiner EF, Avadhani R et al (2022) Intraventricular hemorrhage expansion in the CLEAR III Trial: a post hoc exploratory analysis. Stroke 53(6):1847–1853
8. Cordonnier C, Demchuk A, Ziai W, Anderson CS (2018) Intracerebral haemorrhage: current approaches to acute management. Lancet 392(10154):1257–1268
9. Bu Y, Chen M, Gao T, Wang X, Li X, Gao F (2016) Mechanisms of hydrocephalus after intraventricular haemorrhage in adults. Stroke Vasc Neurol 1(1):23–27
10. Greenberg SM, Ziai WC, Cordonnier C, Dowlatshahi D, Francis B, Goldstein JN et al (2022) 2022 guideline for the management of patients with spontaneous intracerebral hemorrhage: a guideline from the American Heart Association/American Stroke Association. Stroke 53(7):e282–e361
11. van Solinge TS, Muskens IS, Kavouridis VK, Gormley WB, Mekary RA, Broekman MLD et al (2020) Fibrinolytics and intraventricular hemorrhage: a systematic review and meta-analysis. Neurocrit Care 32(1):262–271
12. Huttner HB, Tognoni E, Bardutzky J, Hartmann M, Köhrmann M, Kanter IC et al (2008) Influence of intraventricular fibrinolytic therapy with rt-PA on the long-term outcome of treated patients with spontaneous basal ganglia hemorrhage: a case-control study. Eur J Neurol 15(4):342–349
13. Hanley DF, Lane K, McBee N, Ziai W, Tuhrim S, Lees KR et al (2017) Thrombolytic removal of intraventricular haemorrhage in treatment of severe stroke: results of the randomised, multicentre, multiregion, placebo-controlled CLEAR III trial. Lancet 389(10069):603–611
14. Moradiya Y, Murthy SB, Newman-Toker DE, Hanley DF, Ziai WC (2014) Intraventricular thrombolysis in intracerebral hemorrhage requiring ventriculostomy: a decade-long real-world experience. Stroke 45(9):2629–2635
15. Naff N, Williams MA, Keyl PM, Tuhrim S, Bullock MR, Mayer SA et al (2011) Low-dose recombinant tissue-type plasminogen activator enhances clot resolution in brain hemorrhage: the intraventricular hemorrhage thrombolysis trial. Stroke 42(11):3009–3016
16. Ullman NL, Tahsili-Fahadan P, Thompson CB, Ziai WC, Hanley DF (2019) Third ventricle obstruction by thalamic intracerebral

hemorrhage predicts poor functional outcome among patients treated with alteplase in the CLEAR III Trial. Neurocrit Care 30(2):380–386
17. Luong CQ, Nguyen AD, Nguyen CV, Mai TD, Nguyen TA, Do SN et al (2019) Effectiveness of combined external ventricular drainage with intraventricular fibrinolysis for the treatment of intraventricular haemorrhage with acute obstructive hydrocephalus. Cerebrovasc Dis Extra 9(2):77–89
18. Abdelmalik PA, Ziai WC (2017) Spontaneous intraventricular hemorrhage: when should intraventricular tPA be considered? Semin Respir Crit Care Med 38(6):745–759
19. Varela S, Carrera D, Elazim AA, Robinson MB, Torbey M, Carlson AP (2022) Continuous tissue plasminogen activator infusion using a minimally invasive irrigating catheter for the treatment of intraparenchymal hemorrhage within the basal ganglia: case reports. Oper Neurosurg (Hagerstown) 23(6):e387–e391
20. Carrera DA, Marsh LM, Roach JJ, Sarangarm P, Cole CD, Torbey MT, et al. (2023) HummingFlow: novel single twist-drill access for ventricular drainage, irrigation, monitoring, and automated local drug delivery in subarachnoid hemorrhage. J Neurosurg 1–6. https://doi.org/10.3171/2023.2.JNS23295
21. Hanley DF, Thompson RE, Rosenblum M, Yenokyan G, Lane K, McBee N et al (2019) Efficacy and safety of minimally invasive surgery with thrombolysis in intracerebral haemorrhage evacuation (MISTIE III): a randomised, controlled, open-label, blinded endpoint phase 3 trial. Lancet 393(10175):1021–1032
22. Morgan TC, Dawson J, Spengler D, Lees KR, Aldrich C, Mishra NK et al (2013) The modified Graeb score. Stroke 44(3):635–641
23. Müller A, Mould WA, Freeman WD, McBee N, Lane K, Dlugash R et al (2018) The incidence of catheter tract hemorrhage and catheter placement accuracy in the CLEAR III Trial. Neurocrit Care 29(1):23–32
24. von Elm E, Altman DG, Egger M, Pocock SJ, Gøtzsche PC, Vandenbroucke JP (2007) The Strengthening the Reporting of Observational Studies in Epidemiology (STROBE) statement: guidelines for reporting observational studies. Lancet 370(9596):1453–1457
25. Saliege M, Boyer-Grand A, Lemaire JJ, Chopineau J, Sautou V, Gabrillargues J, et al., (2010) editors. Agarose gels: model of artificial brain in neurosurgery. 39th European Symposium on Clinical Pharmacy, European Society of Clinical Pharmacy; 2010–10–21; Lyon, France https://hal.science/hal-01899202/document
26. Chen ZJ, Gillies GT, Broaddus WC, Prabhu SS, Fillmore H, Mitchell RM et al (2004) A realistic brain tissue phantom for intraparenchymal infusion studies. J Neurosurg 101(2):314–322
27. Fitzgerald ST, Liu Y, Dai D, Mereuta OM, Abbasi M, Larco JLA et al (2021) Novel human acute ischemic stroke blood clot analogs for in vitro thrombectomy testing. AJNR Am J Neuroradiol 42(7):1250–1257
28. Mendelow AD, Gregson BA, Fernandes HM, Murray GD, Teasdale GM, Hope DT et al (2005) Early surgery versus initial conservative treatment in patients with spontaneous supratentorial intracerebral haematomas in the International Surgical Trial in Intracerebral Haemorrhage (STICH): a randomised trial. Lancet 365(9457):387–397
29. Jaffe J, Melnychuk E, Muschelli J, Ziai W, Morgan T, Hanley DF, et al. (2012) Ventricular catheter location and the clearance of intraventricular hemorrhage. Neurosurgery. 70 (5):1258–63; discussion 63–4. https://doi.org/10.1227/NEU.0b013e31823f6571
30. Hinson HE, Melnychuk E, Muschelli J, Hanley DF, Awad IA, Ziai WC (2012) Drainage efficiency with dual versus single catheters in severe intraventricular hemorrhage. Neurocrit Care 16(3):399–405
31. Gonzalez W, Forman E, Stretz C, Potter NS, Wendell LC, Reznik M et al (2022) Abstract TP113: association of external ventricular drain duration and outcomes in aneurysmal subarachnoid hemorrhage. Stroke 53(Suppl_1):ATP113-ATP
32. Hagel S, Bruns T, Pletz MW, Engel C, Kalff R, Ewald C (2014) External ventricular drain infections: risk factors and outcome. Interdiscip Perspect Infect Dis 2014:708531
33. Jaradat RW, Lahlouh AB, Alshogran OY, Aldabbour BA, Balusha AA (2019) Nosocomial infections among patients with intracranial hemorrhage: a retrospective data analysis of predictors and outcomes. Clin Neurol Neurosurg 182:158–166
34. Garavaglia J, Hardigan T, Turner R, Monachello G, Khan MB, Hodge JO, et al. (2023) Continuous intrathecal medication delivery with the IRRAflow catheter: pearls and early experience. Oper Neurosurg (Hagerstown) https://doi.org/10.1227/ons.0000000000000940
35. Dey M, Jaffe J, Stadnik A, Awad IA (2012) External ventricular drainage for intraventricular hemorrhage. Curr Neurol Neurosci Rep 12(1):24–33
36. Hughes JD, Puffer R, Rabinstein AA (2015) Risk factors for hydrocephalus requiring external ventricular drainage in patients with intraventricular hemorrhage. J Neurosurg 123(6):1439–1446
37. Zheng WJ, Li LM, Hu ZH, Liao W, Lin QC, Zhu YH et al (2018) Bilateral external ventricular drains increase ventriculostomy-associated cerebrospinal fluid infection in low modified Graeb score intraventricular hemorrhage. World Neurosurg 116:e550–e555
38. Nishikawa T, Takehira N, Matsumoto A, Kanemoto M, Kang Y, Waga S (2007) Delayed endoscopic intraventricular hemorrhage (IVH) removal and endoscopic third ventriculostomy may not prevent consecutive communicating hydrocephalus if IVH removal was insufficient. Minim Invasive Neurosurg 50(4):209–211
39. Longatti PL, Martinuzzi A, Fiorindi A, Maistrello L, Carteri A (2004) Neuroendoscopic management of intraventricular hemorrhage. Stroke 35(2):e35–e38
40. Longatti P, Fiorindi A, Martinuzzi A (2005) Neuroendoscopic aspiration of hematocephalus totalis: technical note. Neurosurgery. 57(4 Suppl):E409 (**discussion E**)
41. Komatsu F, Komatsu M, Wakuta N, Oshiro S, Tsugu H, Iwaasa M et al (2010) Comparison of clinical outcomes of intraventricular hematoma between neuroendoscopic removal and extraventricular drainage. Neurol Med Chir (Tokyo) 50(11):972–976
42. Song P, Duan F-l, Cai Q, Wu J-l, Chen X-b, Wang Y et al (2018) Endoscopic surgery versus external ventricular drainage surgery for severe intraventricular hemorrhage. Curr Med Sci 38(5):880–7
43. Chen CC, Liu CL, Tung YN, Lee HC, Chuang HC, Lin SZ et al (2011) Endoscopic surgery for intraventricular hemorrhage (IVH) caused by thalamic hemorrhage: comparisons of endoscopic surgery and external ventricular drainage (EVD) surgery. World Neurosurg 75(2):264–268
44. Shimizu Y, Tsuchiya K, Fujisawa H (2019) Endoscopic surgery for thalamic hemorrhage with intraventricular hemorrhage: effects of combining evacuation of a thalamic hematoma to external ventricular drainage. Asian J Neurosurg 14(4):1112–1115